Technical Advances in Ear Reconstruction with Autogenous Rib Cartilage Grafts: Personal Experience with 1200 Cases

Burt Brent, M.D.

Woodside, Calif.

Through the author's experience with 1200 cases during a 25-year period, this article presents technical improvements in ear reconstruction and proposes and discusses possible directions for further technical advancement. This article presents the rationale for the author's current methods of managing total ear repair. Throughout the article, the author stresses and demonstrates cartilage-sparing techniques that are designed to minimize the amount of cartilage used in a repair to preserve maximum chest wall integrity. This article also presents the latest method of framework fabrication, showing differences in construction between younger and older patients; a new method that constructs a tragus as an integral part of the framework; a method that maintains ear projection with a scalp-banked cartilage wedge; and a method that solves the always frustrating low hairline by presurgical laser treatment. In addition, the concept of creating autogenous frameworks by tissue engineering is pursued and discussed in practical clinical terms. A survey of 1000 microtia patients indicates that surgically constructed ears remain durable, withstand trauma well, and provide consistent emotional relief and psychological benefits through the repair. (*Plast. Reconstr. Surg.* 104: 319, 1999.)

Perhaps no area in plastic surgery demands more attention to detail than ear reconstruction, for which autogenous tissue clearly continues to be the material of choice for repair. It is the purpose of this article to focus on technical improvements that have evolved from my 25-year experience with more than 1200 cases and to introduce and discuss future directions of this challenging surgical art form.

The material presented herein is derived from clinical experience with congenital microtia (1094 completed ears in 1000 patients; 94 cases were bilateral) and traumatic injuries (125 completed cases of total ear reconstruction). This article focuses on total repair of major congenital ear defects but includes relevant supplementary input from experience gained by managing traumatic auricular deformities. All repairs used autogenous rib cartilage grafts.

Patients

Of the 1000 microtia patients in this series, 582 were right (58.2 percent), 324 were left (32.4 percent), and 94 were bilateral (9.4 percent). A total of 631 (63.1 percent) of the patients were male, and 369 (36.9 percent) were female (Table I). Problems associated with microtia were frequent. Among these, the most common were branchial arch deformities; 36.5 percent had some flattening of the involved facial half, and 15.2 percent exhibited facial nerve weakness. Other common problems included cleft lip and/or palate (4.3 percent), urogenital defects (4 percent), cardiovascular malformations (2.5 percent); and macrostomia (2.5 percent) (Table II). Family history revealed 4.9 percent recurrence within the immediate family. When distant relatives were included, this number increased to 10.3 percent.

Initiating the Surgery

At consultation, the family is anxious to have the ear repaired as soon as possible, but it is important for the surgeon to wait until it is technically feasible. There usually is enough

From El Camino Hospital, Mountain View, California, and the Division of Plastic Surgery, Stanford University Medical Center. Received for publication January 18, 1999.

Presented at the Annual Meeting of the American Association of Plastic Surgeons, in Colorado Springs, Colorado, May 4, 1999.

TABLE I
Series of 1000 Microtia Patients

Side	Cases (n = 1000)	Percent	Total Ears (n = 1094)	Sex	n	Percent
Right	582	58.2	582	M	631	63.1
Left	324	32.4	324	F	369	36.9
Bilateral	94	9.4	188			

rib cartilage to serve as the sculpting medium by age 6, and at the urging of the parents, I often begin at that time. If not pressured by the family, my favored age to begin surgery is between 7 and 8 years, when the child is more aware of, and concerned with, the problem, usually wants it resolved as much as family members do, and is helpful and cooperative during the postoperative care phase.

Of the 1000 microtia patients in this series, 28 (2.8 percent) were operated on at 5½ years, 472 (47.2 percent) at age 6 or 7, 211 (21.1 percent) between ages 8 and 10, 143 (14.3 percent) between ages 11 and 15, 74 (7.4 percent) between ages 16 and 20, 65 (6.5 percent) between ages 21 and 40, and 7 (0.7 percent) between ages 41 and 62 (Table III).

Selecting the Method of Framework Fabrication

In contrast to alloplastic frameworks, which often fail,[1] and homologous cartilage, which absorbs,[2] autogenous cartilage produces favorable results, experiences few complications, and withstands trauma.[3–5] I have seen silicone ear frameworks lost to even minor trauma as many as 12 years after implantation. Despite some investigators' enthusiasm with Medpore frameworks[6–8] (Porex Surgical, Inc., College Park, Ga.), these foreign substances seem to encounter the same problems that have plagued silicone. Most recently, a patient came to my consultation with an infected sinus tract that had been draining from her Medpore implant for 2 years; another patient presented with three separate exposed areas of Medpore in his reconstructed ear. On the other hand, after the 10th postoperative day has passed safely, I have never lost an autogenous ear framework in a microtia patient; only one framework has been lost in a trauma patient with poor compliance to postoperative instructions. To date, among my patients, more than 70 reconstructed ears have survived major trauma.

For many years, there has been considerable interest in creating a prefabricated framework from autogenous cartilage to circumvent the necessity of sculpting an ear framework during a prolonged reconstructive procedure or to circumvent the need for artistic ability to create a realistic ear framework from rib cartilage. In the 1940s, Young[9] and Peer[10] first conceived the idea of framework prefabrication before the actual auricular reconstruction. This innovative technique was accomplished by means of diced pieces of autogenous rib cartilage, which were placed in a fenestrated two-piece, ear-shaped Vitallium mold, which in turn was banked in the patient's abdominal wall. After several months, the banked mold was retrieved and opened, and the framework of cartilage chips, which had united by connective tissue that had grown through the openings of the mold, was harvested. However, the results were not consistent, perhaps because contraction of the fibrous tissue surrounding the multiple car-

TABLE II
Associated Deformities

Type	Percent
Branchial arch deformities	
Obvious bony and soft-tissue deficit	36.5
Family perceives it as "significant"	49.4
Overt facial nerve weakness	15.2
Of these, more than one branch involved	42.6
Macrostomia	2.5
Cleft lip and/or palate	4.3
Urogenital defects	4.0
Cardiovascular malformations	2.5
Miscellaneous deformities	1.7

TABLE III
Ages Operated On

Age Range (years)	Patients n = 1000	Percent of Total
5½	28	2.8
6–7	472	47.2
8–10	211	21.1
11–15	143	14.3
16–20	74	7.4
21–40	65	6.5
41–62	7	0.7

tilage islands distorted the resulting framework.

Recently, interest in this prefabrication concept has been rekindled through modern techniques of tissue engineering, in which bovine cartilage cells are grown in the laboratory and seeded upon a synthetic, biodegradable ear form, which is then implanted beneath the skin of an immuno-incompetent mouse.[11] The early results are interesting, but one should note that the trial work does not take place in conditions that are comparable to those of a clinical human ear reconstruction—the investigators' framework is placed under the loose skin of the back of an animal, whereas a surgeon's framework for ear repair is placed underneath tight skin, just anterior to the scalp hairline in the ear region.

Although these new laboratory studies are intriguing, unless a very firm, substantial three-dimensional framework can be produced from autogenous tissues, it will likely suffer the same fate I observed of the prefabricated frameworks of Young[9] and Peer[10]; i.e., the framework was flattened by the pressure of the taut, two-dimensional skin envelope under which it was placed to complete the ear reconstruction. The other obvious limitation of prefabricated ear frameworks is the difficulty in producing the great variation in size and shape that is necessary to match the opposite, normal ear. When sculpting directly from rib cartilage, these lim-

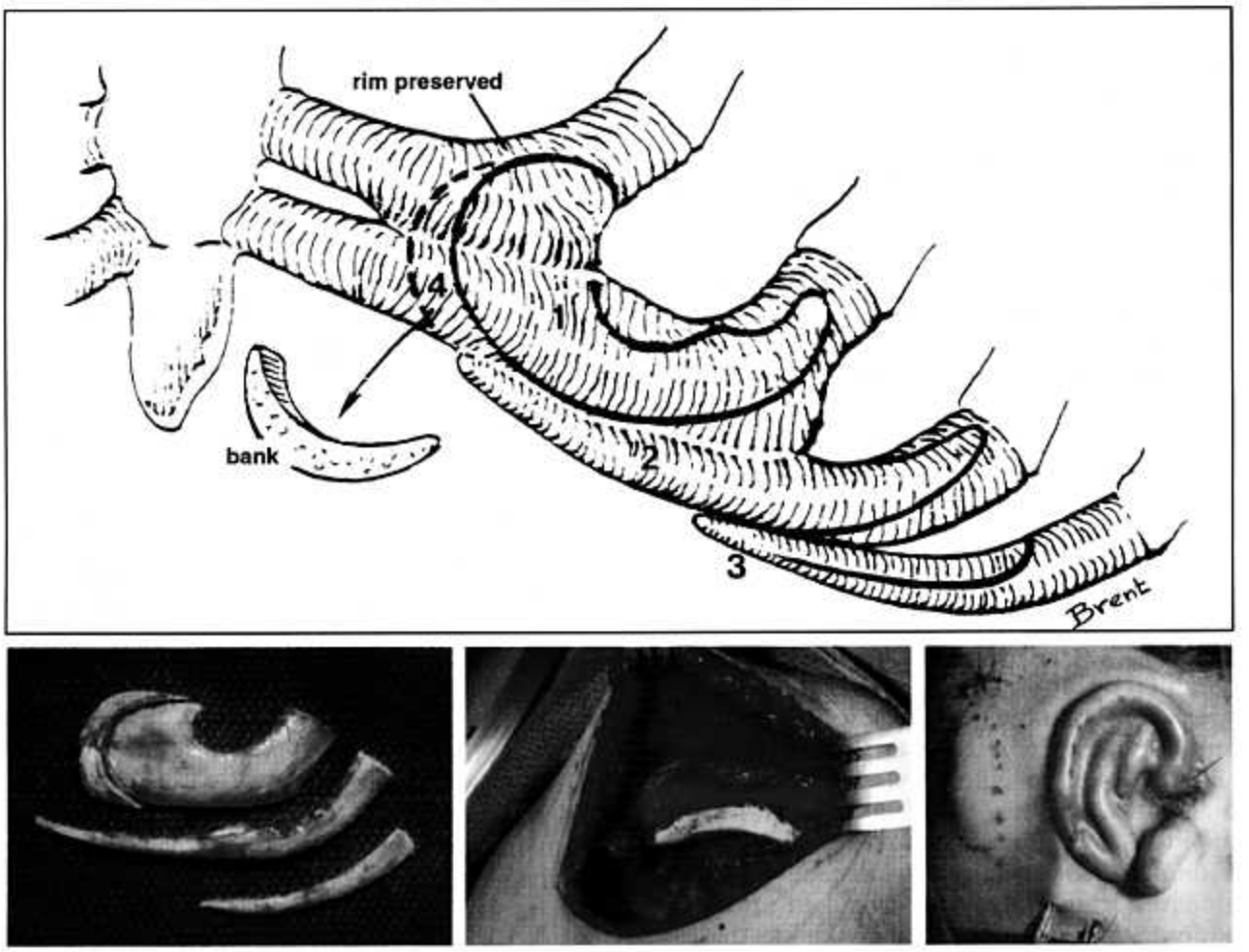

FIG. 1. Preserving maximum chest wall integrity: harvesting minimal rib cartilage for ear framework fabrication. (*Above*) Rib cartilages used in total ear construction: 1, synchondrotic block used for body of framework; 2, floating rib used for helix; 3, strut used for tragus (see Figs. 2 and 3); 4, extra cartilage wedge to be banked for use during the elevation procedure. (*Below, left*) Harvested rib cartilages, as depicted in the drawing above. (*Below, center*) Preserved rim maintains chest wall integrity by tethering 6th cartilage to sternum (see text). (*Below, right*) Banking the extra cartilage wedge under the scalp, posterior to but not in continuity with the main ear "pocket." This banked wedge will be harvested and used during the elevation procedure (see text and Fig. 9). Note position of suction drains: the anterior drain passes under frame, through conchal region, then over the inferior crus; the posterior drain courses behind the frame then above the helix.

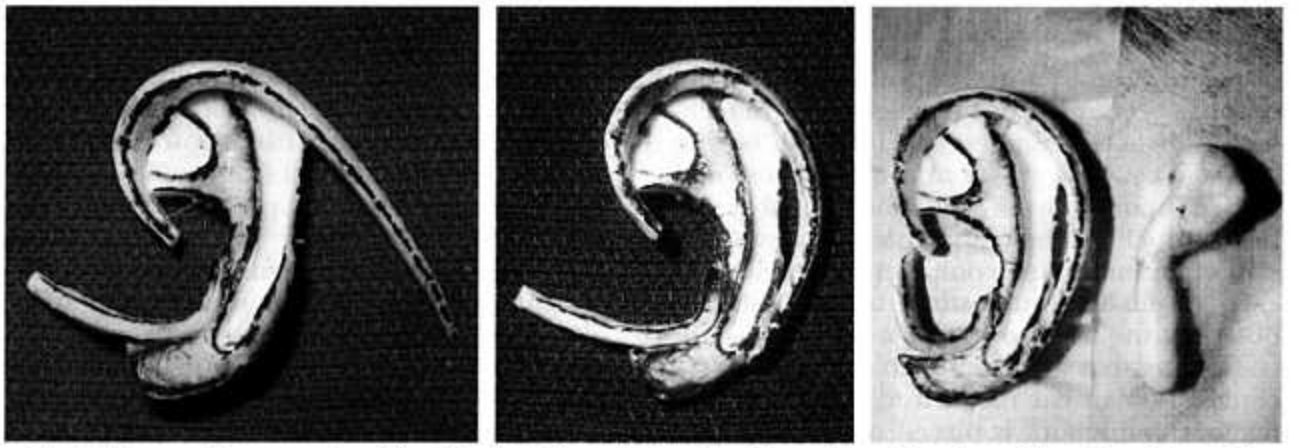

FIG. 2. Framework construction with minimal cartilage: dealing with skimpy rib configurations. When there is insufficient cartilage for the main block, I employ the "expansile" design[18] and gain frame width by bowing out the helix and leaving an open space in the scaphal region. This is preferable to violating the 6th rib margin to get more width, which risks deforming the chest wall (see text).

itations do not exist because the surgeon creates the required specific size and shape for each ear reconstruction.

However, even I have long been intrigued by the concept of creating a prefabricated cartilaginous ear framework. Consequently, I am working with researchers at New York University Medical Center[12] to explore the possibilities of bioengineering frameworks of firm, autogenous cartilage, to see if some of the aforementioned limitations can be overcome.[13] Our direction involves growing autogenous costal cartilage in molds of varying sizes made from idealized frameworks that I have sculpted and cast. But to fill these molds with chondrocytes obtained by digesting a large volume of rib cartilage would merely be reproducing Young's and Peer's work using modern technology. Our goal is to exploit the technology by using a small piece of cartilage (perhaps obtained by biopsy from the microtia patient at age 3 to 4 years, when neochondrogenic potential is high), to extract the chondrocytes, to expand them in culture, and then to infuse them into the ideal matricial substrate within the ideal ear framework mold for each specific patient. Once generated to satisfaction, the engineered framework is then banked under the patient's hairless periauricular skin, as the first reconstructive surgical phase. For this technique to be successful, the major problems entail replicating sufficient chondrocytes from a small cartilage sample (25 to 50 million cells/ml are necessary for neocartilage formation in a construct, and the ear mold volume is approximately 5 cc); and regenerating firm cartilage matrix from those chondrocytes so that the engineered three-dimensional framework can withstand the pressure caused by the constraints of a two-dimensional skin cover that is taut, inelastic, and restrictive.

In my experience, until tissue engineering evolves beyond the aforementioned problems, sculpted autogenous rib cartilage remains the material of choice for surgical repair of the ear.

SURGICAL STAGING

Because a framework of well-sculpted cartilage is the foundation of the repair, it must be created under ideal conditions. Ideally, this is accomplished as the first surgical stage, in which one usually finds scar-free skin with optimal circulation and elasticity. Secondary procedures such as repositioning the earlobe and creating the auriculocephalic sulcus take place only after sound healing of the grafted cartilage framework foundation. Combining procedures to reduce surgical stages[14] must be done with caution to prevent complications[15] and to ensure predictability of the repair. One will not be thanked by a patient for taking short cuts, but instead will suffer with the family during management of a complication that arises from doing so.

THE FIRST SURGICAL STAGE

Harvesting the Rib Cartilage

To avoid deforming the thorax, certain precautions must be followed to obtain the ideal sculpting material. In a survey addressing my first 500 microtia patients, I learned that 35.2

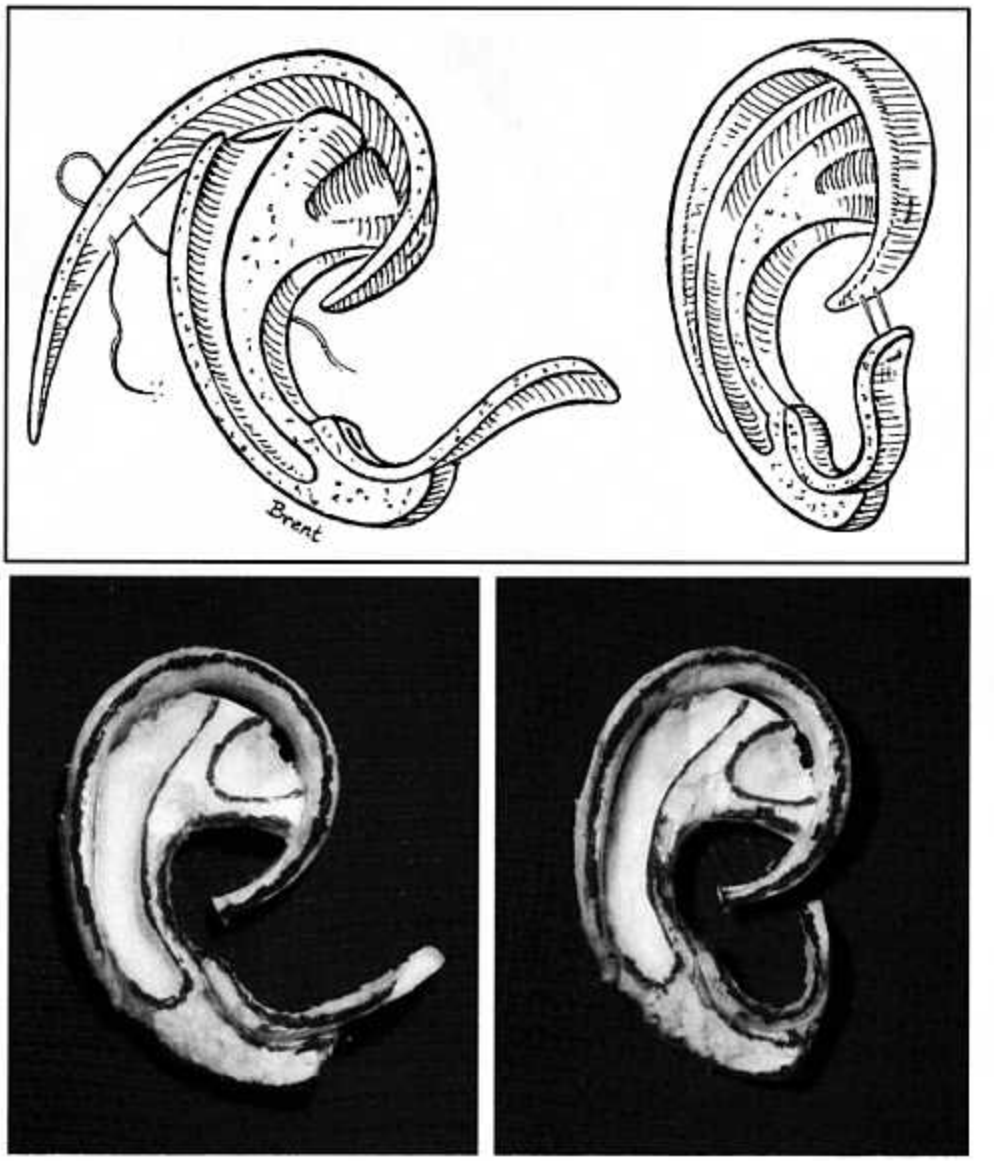

FIG. 3. Ear framework fabrication with integral tragal strut. (*Above*) Construction of the frame. The floating cartilage creates a helix, and second strut is arched around to form the antitragus, intertragal notch, and tragus. This arch is completed when the tip of the strut is affixed to the crus helix of the main frame with horizontal mattress suture of clear nylon. (*Below*) Actual framework fabrication with the patient's rib cartilage.

percent of patients rated the scar and/or chest contour as "noticeable, but worth the tradeoff."[5] One only has to observe a surgically deformed thorax to realize the importance of harvesting only what is needed to create the framework, thus preserving maximum integrity of the chest wall. Obvious chest deformities[16,17] can be decreased significantly by preserving even a minimal rim of the upper margin of the sixth rib cartilage to obtain the basic ear shape of the framework (Fig. 1). This precautionary measure retains a tether to the sternum so that the rib does not flare outward, thus distorting the chest as the child grows. If the synchondrotic region seems inadequate in width, one can compensate for framework width by bowing the helix away from the framework body (the expansile design[18]) rather than violating the sixth rib margin and sacrificing chest wall integrity (Fig. 2). To acquire cartilage of appropriate configuration, I prefer to use the contralateral chest.

Fabricating the Framework

The framework must be treated as a living sculpture. During fabrication, I avoid the use

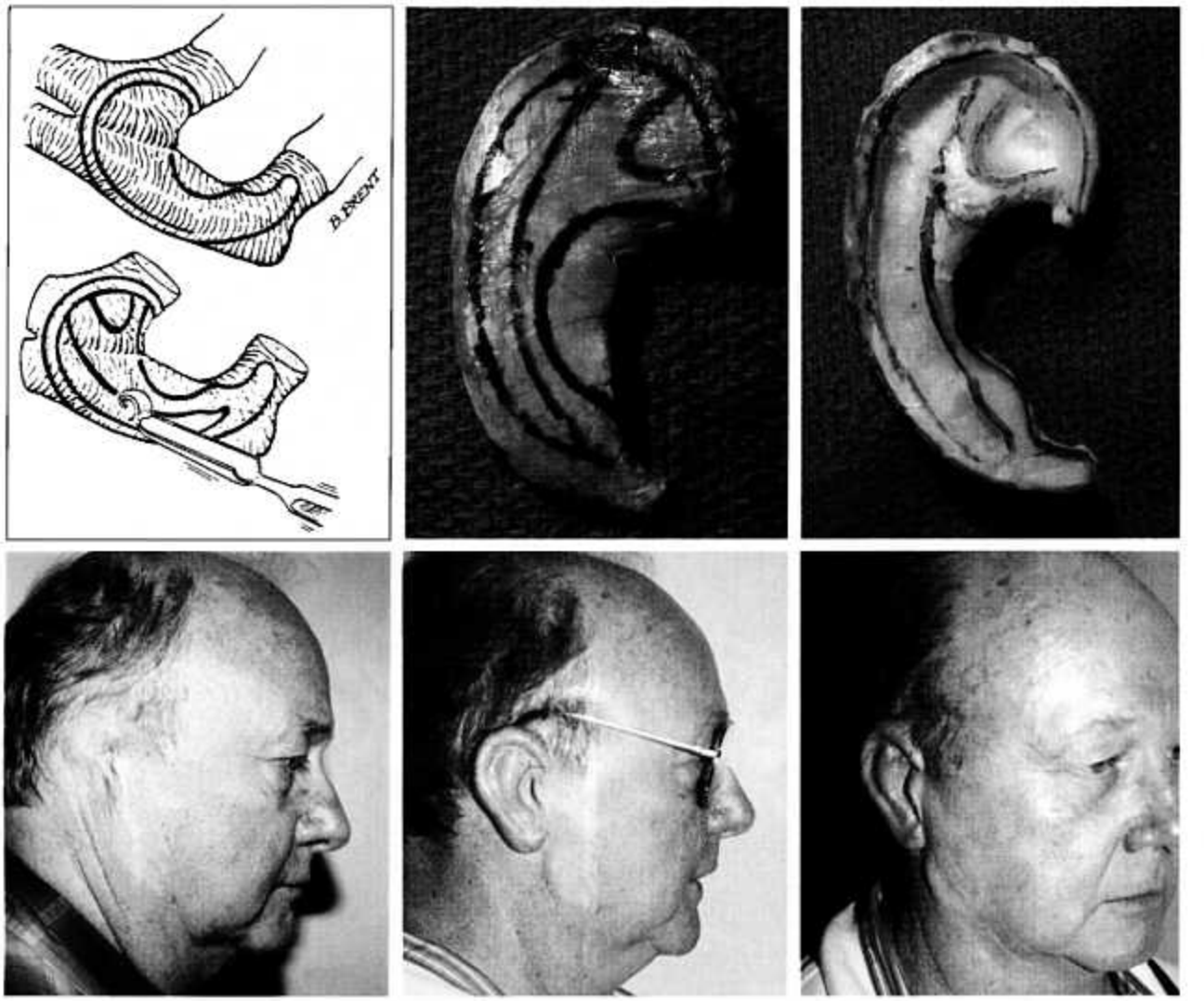

FIG. 4. Framework modifications in the adult patient. (*Above, left*) When a solid, fused cartilage block is encountered, the framework is sculpted in one piece. (*Above, center*) Cartilage block marked for carving. (*Above, right*) Completed framework, sculpted from the block. (*Below, left*) A 60-year-old man with traumatic total ear loss. (*Below, center* and *right*) Result achieved with a one-piece sculpture from a fused cartilage block, 1 year postoperatively. Simulation of the absent earlobe was achieved by sculpting its likeness in the framework's inferior pole.

of power tools by carving the tissue with scalpels and chisels; the cartilage is intermittently bathed in saline to prevent desiccation. I remove muscle and connective tissue scraps from the cartilage graft before carving, but I preserve perichondrium, when possible, to facilitate adherence to and subsequent nourishment from the skin cover. Upon forming the basic shape of the ear, the helix is created by thinning the floating rib cartilage. To decrease the amount of foreign bodies, the helix is wrapped around the ear silhouette with a minimal number of 4-0 and 5-0 clear nylon sutures (Fig. 3, *above*). The knots are placed on the undersurface of the framework. I find that nylon causes far fewer problems than wire sutures, which commonly extrude from reconstructed ears.[19,20]

Although in the past I relied almost totally on creating the tragus with composite grafts during a separate procedure,[21] I have recently developed a new method to create the tragal strut as part of the original framework itself (Fig. 3). This is particularly useful in the case of bilateral microtia, where an appropriate donor site for composite tissue is unavailable. As with the original principle of expansile framework,[18] this new method of tragus construction uses cartilage more efficiently so that one needs only a minimal extra strut of rib tissue

(Figs. 2 and 3). As mentioned before, such considerations are preeminent in preserving chest wall integrity and contour.

Framework Modifications in Older Patients

In adult patients, I usually find that basic differences in rib cartilage quality and configuration require that I modify the framework fabrication. Adult rib cartilages often are fused into a solid block (Fig. 4, *above, center*), which invites one to sculpt the framework as one piece—not unlike a wood carving (Fig. 4, *above, right*). In my experience, this is particularly advantageous because adult cartilage is often calcified; it is difficult, if not impossible, to create a separate helix that will bend without breaking. If a one-piece carving produces insufficient helical projection, one can detach the helix and slide it up the framework body to augment the protrusion of rim (Fig. 5, *above left*). This improved contour is maintained by reattaching the helix to the framework with several permanent sutures (Fig. 5, *below*).

The Cutaneous Cover

On completion of the framework of carved cartilage, meticulous technique is used to create a skin pocket in the proposed auricular region that will provide a nourishing, protective covering for the newly introduced ear framework. As time elapses during the rib harvest and framework fabrication, I minimize contamination risk by preparing and scrubbing the ear region just before beginning the skin dissection.

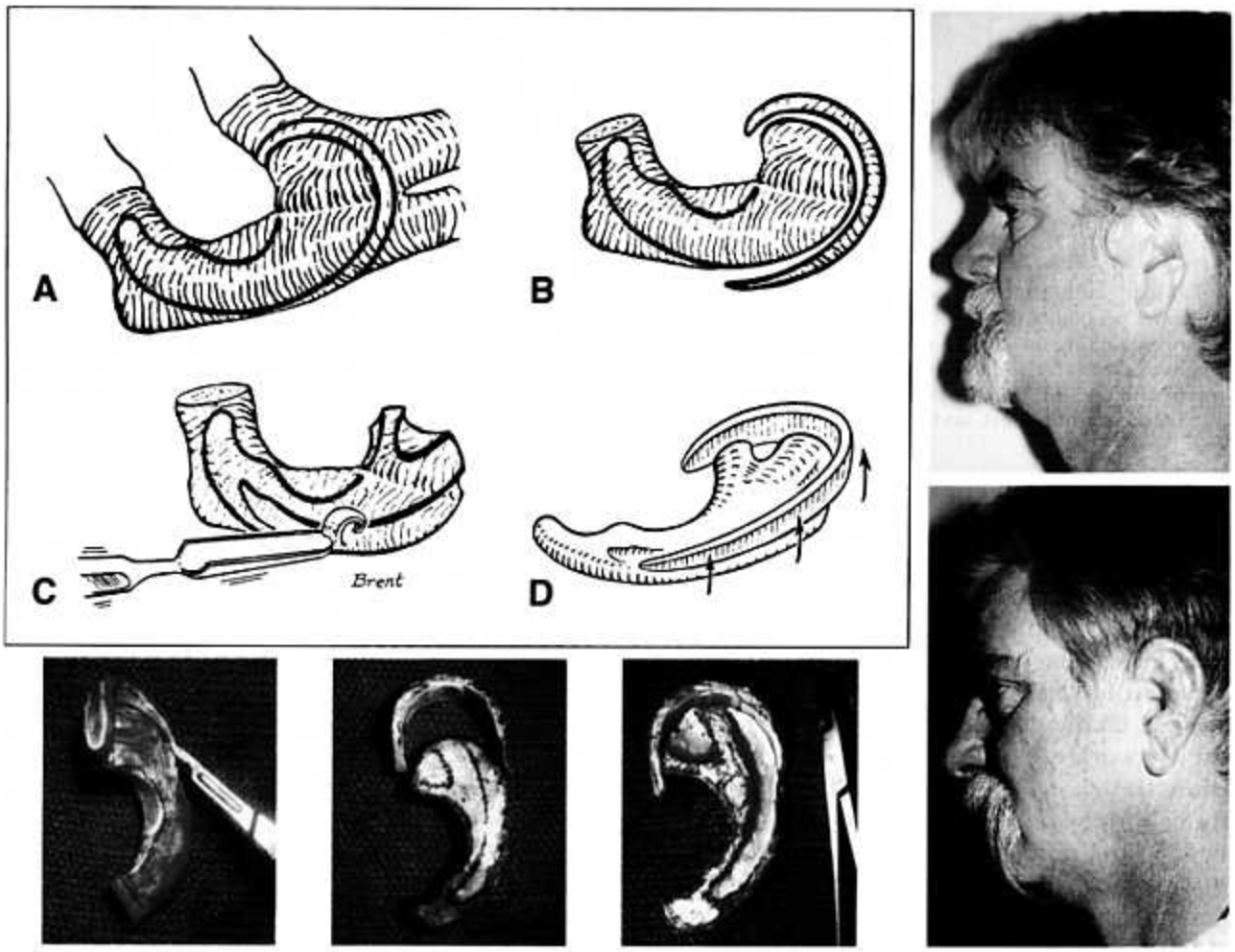

FIG. 5. Maximizing rim projection in adult patient with sliding helical advancement. (*Above, left*) A and B, harvesting fused rib cartilage block and separating the inflexible helical portion; C, sculpting body of framework; D, sliding and reattaching the helix to maximize its projection. (*Above, right*) A 50-year-old man with ear loss from a dog bite. (*Below, left, second from left,* and *third from left*) Construction of the framework using the technique illustrated in the drawings. (*Below, right*) The completed repair. This patient had his hairline "idealized" by laser treatment before the rib cartilage graft (See Fig. 6).

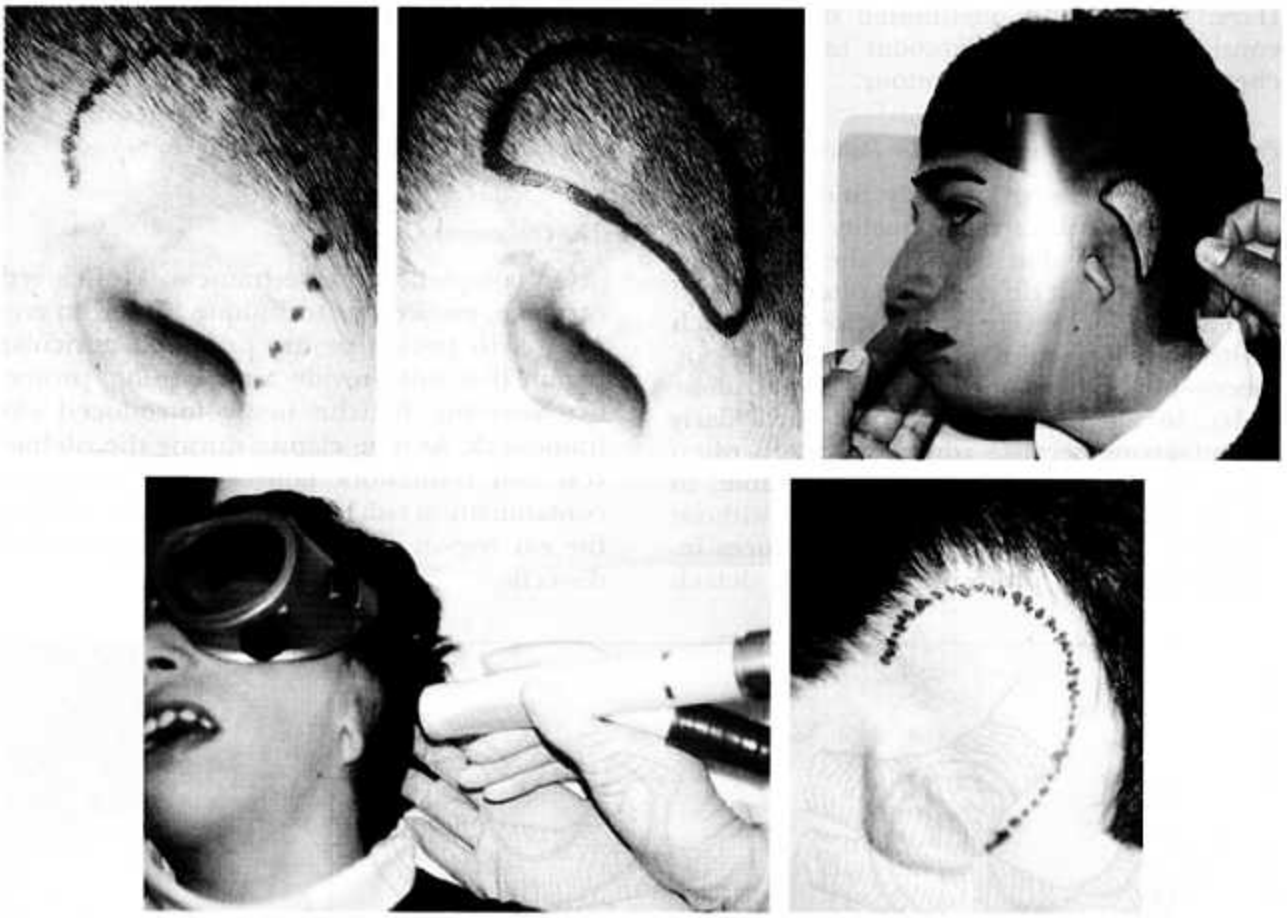

FIG. 6. "Hairline idealization" by presurgical laser treatment. (*Above, left*) Microtia with typical low hairline, which would cover the upper portion of the proposed auricular construction. (*Above, center*) Crescent-shaped area designated for laser de-epilation before embarking on surgical ear repair. (*Above, right*) Film template to aid in relocating the exact crescent during serial laser treatments. Note aids in applying the template: cut-out area slips over vestige; eyebrow, lateral canthus, and oral commissure are marked on film. (*Below, left*) The laser treatment in progress. (*Below, right*) The same microtia after several laser treatments. The hairline is now ideal, and surgical construction of the ear will begin (see Fig. 5, *below, right*).

Using the film template and preoperatively determined measurements, I mark the position of the ear and make a small incision along the backside of the ear vestige. Once I have dissected out and removed the gnarled remnant of cartilage beneath the skin, I use fine dissection scissors to develop a thin skin pocket, taking great care to prevent damage of the network of small blood vessels that nourishes the skin. To furnish sufficient, tension-free skin coverage, I carry the dissection well beyond the marked ear outline. After securing hemostasis, I insert two small silicone drains beneath and behind the framework (Fig. 1, *below, right*), which are attached to vacuum test tubes. This creates a continuous suction that promotes adherence of the nourishing skin flap to the cartilage sculpture and prevents disastrous hematomas.

Postoperative Course

I pack the convolutions of the constructed ear with Vaseline gauze, then apply a bulky, noncompressive dressing. Because the vacuum system provides both skin adherence and hemostasis, pressure is unnecessary and contraindicated. On the first day, the tubes are changed frequently by the ward nurses. The patient leaves the hospital in 24 to 48 hours, after which time I teach the parents to change the tubes several times daily. I remove the drains on the fifth postoperative day, when drainage is minimal and the skin is well adhered to the cartilage framework.

The first day after surgery, the patient often experiences chest discomfort from the rib surgery and nausea from the anesthesia. Both of these are easily controlled with medications. Most patients do not experience significant ear

FIG. 7. Utilizing vestiges. (*Above, left* and *second from left*) A 7-year-old boy with grade II microtia. (*Above, second from right*) Native auricular cartilage shelled out from the skin envelope and replaced with sculpted rib cartilage graft. Note that to avoid closing the incision under tension, it was repaired with a full-thickness skin graft. (*Above, right*) Result achieved. (*Second row, left*) A 14-year-old patient with unusual, convoluted microtia vestige. (*Second row, second from left*) Primary rib cartilage graft with partial vestige excision. (*Second row, second from right*) Earlobe transposition and further excision of vestigial tissues. (*Second row, right*) Continued repair. Further vestige excision is planned. (*Third row, left*) A 20-year-old patient with traumatic ear loss from a human bite. (*Third row, second from left*) Placement of the rib cartilage graft, immediately postoperative. Note the site through which the skin pocket was developed; the inferior portion of the dissection was accomplished through a small incision on the backside of the earlobe vestige. (*Third row, second from right*) Inset of lobule. (*Third row, right*) Final result. (*Below, left*) A 6-year-old girl with conchal form microtia. (*Below, second from left*) First-stage repair with a rib cartilage graft. (*Below, second from right*) Second-stage "splice" of the remnant into repair. (*Below, right*) Final result, 2 years postoperatively.

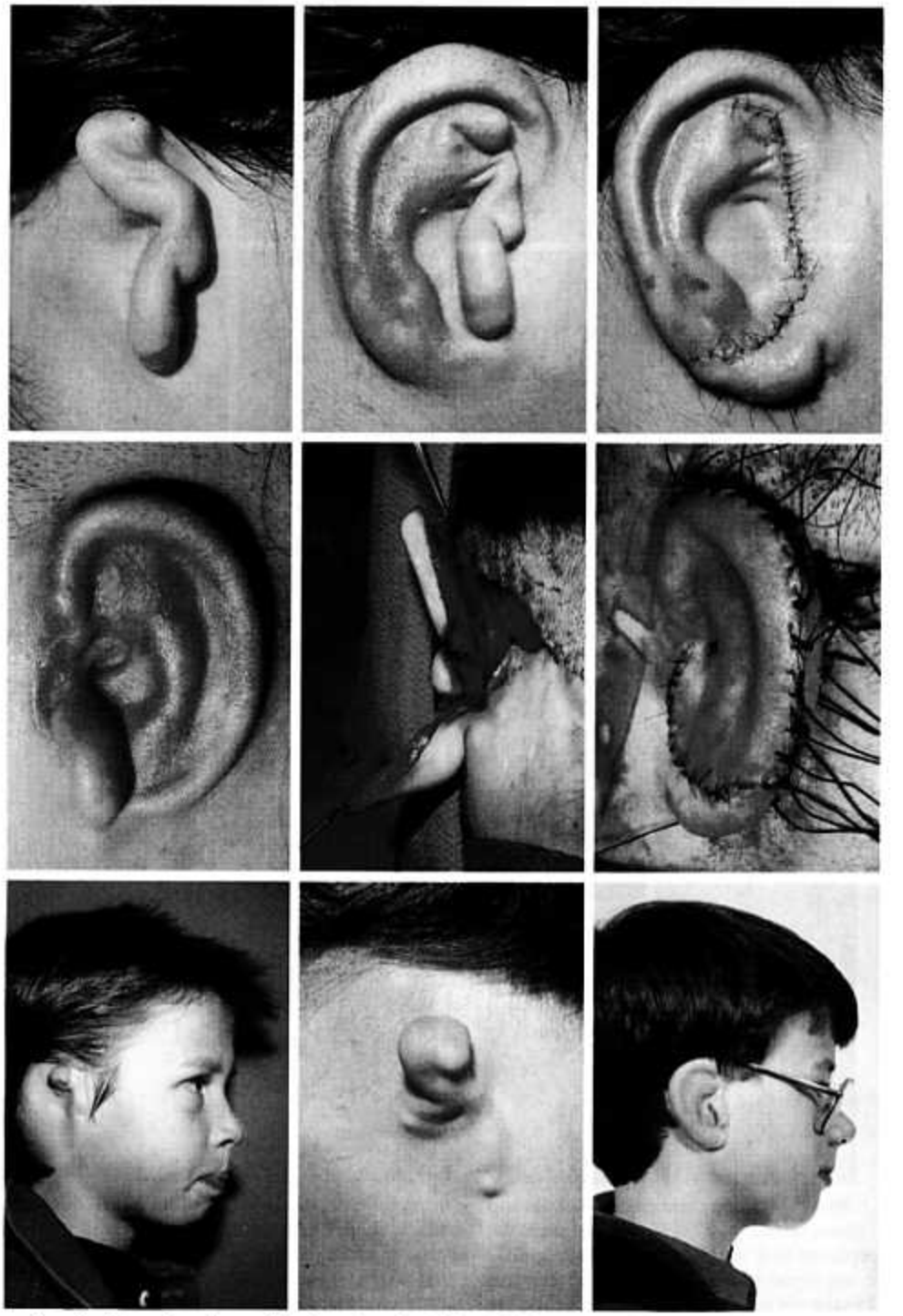

FIG. 8. Managing the earlobe in microtia. (*Above*) Lobe transposition secondary to cartilage framework stage. (*Center*) Lobe transposition combined with an elevation procedure. This was safe because the skin bridge above the short lobule carries circulation across to the auricle (see text). (*Below*) Microtia with absent lobule vestige. The lobe is created by first defining it in the rib carving then further delineating it when the ear is elevated with the skin graft (see also Fig. 4, *below, right*).

discomfort. Most patients run a fever the day after surgery, because they are splinting the chest and trapping lung secretions. To prevent this atelectasis, the patient is encouraged to breathe deeply, aided by the use of a triflow respirometer and by blowing up balloons. Sutures are removed from the ear after 1 week, and bandages are discontinued after approximately 12 days. I permit the patient to resume school 2 weeks after surgery.

Activities and Sports

Children are restricted from sports for 4 to 5 weeks and teenagers and adults for 6 weeks. This regime protects the ear, but more importantly, the chest wound, which is much more significant. Once back to sports, the patient is allowed to play baseball and other sports with no special protection; the patient can perform like anyone else in most activities. Because the reconstructed ear is made from the patient's own living tissues, it grows, heals, and can tolerate as much bumping and trauma as a normal ear. However, I do discourage unusually traumatic activities such as boxing. If the patient chooses to wear a helmet (for motorcycling or football), I suggest that it be modified to accommodate the new ear to avoid scraping inside the helmet. I suggest cutting out an area and lining it with soft foam rubber.

In the past, I preferred that patients avoided sleeping on their surgically constructed ears because I believed that continually doing so might possibly flatten out helix details. How-

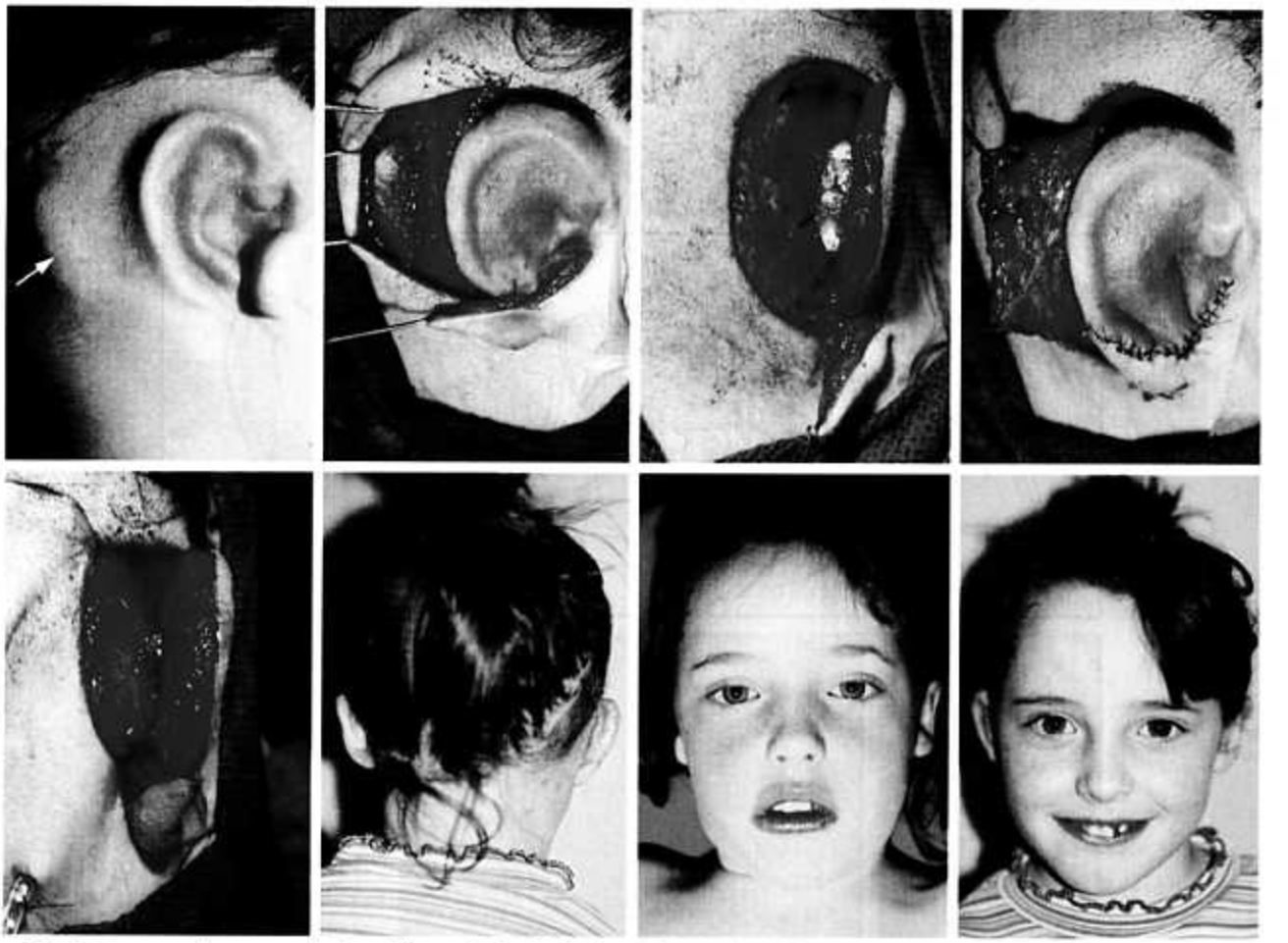

FIG. 9. Augmenting ear projection with a scalp-banked rib cartilage graft and fascial flap; simultaneous earlobe transposition. (*Above, left*) Healed first-stage repair of a microtic ear (same patient as shown in Fig. 1, *below, right*). Note banked rib cartilage behind the ear framework (*arrow*). (*Above, second from left*) Stage 2: retroauricular scalp undermined to retrieve banked cartilage; earlobe transposition begun. (*Above, second from right*) Banked cartilage wedged behind the elevated ear to augment its projection; lobule suspended on the inferior pedicle. (*Above, right*) Retroauricular fascial flap raised; earlobe transposition complete. (*Below, left*) Fascial flap turned over the cartilage wedge to provide a nourishing cover for skin graft. (*Below, second from left*) Complete skin graft "take" on the elevated ear. (*Below, second from right*) Preoperative view of the patient. (*Below, right*) Healed postoperative appearance.

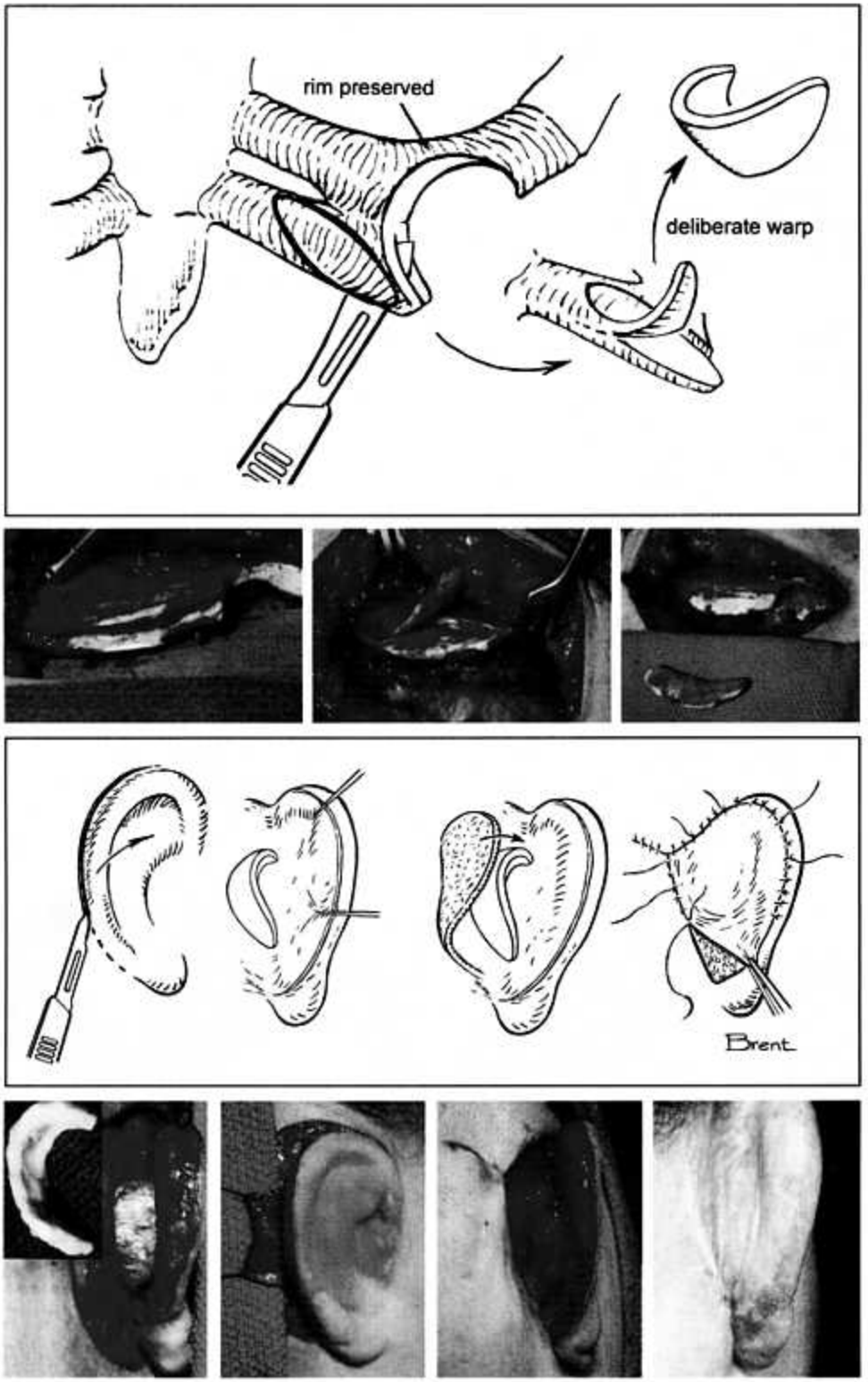

FIG. 10. Augmenting ear projection with split cartilage graft and retroauricular turnover fascial flap. (*Above*) Broad cartilage wedge harvested by splitting rib cartilage. Chest wall integrity is maintained by preserving inner cartilage lamella; the harvested outer lamella predictably warps[37] to favorably shape the posterior conchal wall wedge. (*Second row, left*) Splitting the rib cartilage in situ. (*Second row, center*) Outer cartilage lamella predictably begins to warp. (*Second row, right*) The harvested wedge. Note preserved inner cartilage lamella of the chest wall. The curved cartilage graft is banked subcutaneously until needed for projecting the surgically con-

ever, I have rarely seen this problem during my 25 years of practice. Because everyone turns over while sleeping, it is impossible to keep from rolling over on a reconstructed ear now and then. Patients with bilateral microtia who have had two ears surgically repaired find it impossible to avoid lying on their ears. Therefore, I recommend vigilant protection for 1 month and encourage patients to use very soft pillows (preferably feather down) so that the reconstructed ear is protected from firm pressure. One month after the surgery, sleeping on the ear is no longer an issue.

Managing the Hairline

Low hairline is one of the most common and troublesome problems in auricular construction. Because the normal hairline is usually lower than the apex of a normal ear and sometimes considerably lower in microtia, inserting the framework beneath the periauricular skin often places hair on a portion of the reconstructed auricle.

Dealing with this unwanted hair depends on how much ear is actually involved. If hair is limited to the helix, then electrolysis[22] or clipping is clearly the method of choice. If hair covers one-third or more of the ear, I have often resurfaced the ear with a skin graft (with or without a fascial flap[5]). Regardless of hair quantity, it is ideal to eradicate the hair by nonsurgical means, which eliminates a patchwork appearance and preserves the normal aesthetic and protective qualities of the local skin. Such a depilatory method would be even better if it simultaneously thinned the follicle-containing skin of the scalp to provide the new ear with finer skin coverage. Perhaps in the future both of these goals will be achieved without surgery.

In recent years, lasers have become useful adjuncts for treating the skin and its appendages.[23] It has been found that treating axillary hidradenitis with the laser not only improves that condition by eliminating the apocrine sweat glands[24] but also reduces the bulk of these epidermal appendages, resulting in finer and softer skin.[25] With this concept in mind, I am hopeful that significant reduction of the hair follicles may likewise alter the skin of the scalp so that when it does cover a portion of the ear, it will be thinner and finer, resulting in enhanced detail of the framework.

Although they still do not consistently produce permanent removal, at this writing, laser treatments can favorably deter hair growth to make it both finer and slower. Furthermore, as contrasted to needle electrolysis, patients can tolerate much larger areas of laser treatment during a given session. There are two methods of laser treatment for hair removal. One targets the melanin (and thus, the heavily pigmented follicles) within the depth of the dermis,[26] whereas the other method targets only the follicles by loading them with carbon particles through a gel transport medium and then focusing the laser on the carbon.[27,28] The trick is to deliver enough energy density through the laser to destroy the hair follicles without damaging the skin, which causes scarring and/or hypopigmentation. Presently, laser treatments decrease hair density and texture so that only a few maintenance treatments are needed per year. Laser technology continues to improve with such advances as better coolant techniques, which permit one to safely deliver a higher fluence of energy. Soon, it should consistently be possible to achieve permanent hair removal without injuring surrounding skin.[29]

Currently, I pretreat ear reconstruction patients with the laser to create the ideal hairline before initiating the surgical ear repair (Fig. 6). To aid the laser technician (who often may be at a great distance from my practice), I create a template that makes it easy to precisely relocate the exact target area during the serial treatments (Fig. 6, *above, right*).

Other Stages of the Ear Repair

Earlobe Transposition

Although it is possible to transpose the earlobe at the same time one inserts the cartilaginous framework, I find it safer and aestheti-

structed ear. (*Third row*) Scheme of separating the surgically constructed ear from the head; placing the projection-maintaining cartilage wedge and covering it with turnover flap of retroauricular fascia; then applying split-skin graft. (*Below, left*) Projection of elevated ear augmented with the banked split-cartilage graft. Note how the purposeful warp has remained and produced an ideal shape for the new posterior conchal wall (*inset*). This particular graft had been subcutaneously banked beneath the original chest incision. (*Below, second from left*) Raising the retroauricular fascial flap. (*Below, second from right*) The fascial flap turned over the cartilage wedge, before applying skin graft. (*Below, right*) The healed repair. Note maintenance of projection and auriculocephalic sulcus.

cally better to perform this as a secondary procedure. Nagata[30] and Firmin[31] transpose the earlobe and use skin from the posterior surface of the lobule to line the tragal strut of the framework during the first-stage surgery. Although this does produce an excellent tragal appearance, the price paid is an earlobe that is at times compromised in appearance and often unable to accommodate an earring. This latter problem is no small issue for my young female patients, who often submit to surgery with eventual earlobe piercing as their highest priority (Fig. 7, *below, right*).

If the lobe vestige is short, so that a substantial skin-bridge above can be preserved during its transposition, then one can safely move the earlobe while simultaneously separating the auricle from the head to create the auriculocephalic sulcus and preserving sufficient posterior earlobe skin to permit the use of earrings (Figs. 8, *center*, and 9).

Lifting the Ear

Separating the ear from the head with a skin graft defines the posterior margin of the ear and creates an auriculocephalic sulcus. I make the incision several millimeters peripheral to the embedded framework; then, I sharply lift the ear from its fascial bed while carefully preserving connective tissue on the framework's undersurface, which serves as a nourishing bed for the graft. I harvest a medium split-thickness skin graft from a hidden region (usually underneath the bathing suit area) and suture it to the wound with the sutures left long; these are tied over a bolster to tamponade the graft to the recipient bed.

One can achieve greater projection of the auricle by placing a wedge of rib cartilage behind the elevated ear, but this must be covered with a tissue flap in order for the skin graft to "take" over the cartilage. Nagata[30] accomplishes this with an axial flap of temporoparietal fascia. However, use of that fascial flap invites a certain morbidity.[5] I believe that this fascia should be reserved for significant traumatic and secondary ear reconstruction cases where one relies on a fascial flap for their salvage and repair.[32] Therefore, like Firmin[33] and Weerda,[34] I prefer to cover the cartilage wedge with a turnover "book flap" of occipitalis fascia from behind the ear[35] (Figs. 9, *above, right*, and *below, left*, and 10, *third row* and *below*). When this technique of cartilage-wedging is used, there is no need to subject the patient to a second uncomfortable chest operation by harvesting rib cartilage anew, as does Nagata.[36] Instead, an extra piece of cartilage can be banked underneath the chest incision during the initial first-stage procedure. When the wedge is needed during the elevation procedure, it can be easily retrieved by incising through the original chest scar. Alternatively, I also bank this cartilage wedge underneath the scalp, just posterior to the main pocket where the completed ear framework is placed (Figs. 1, *below, right*, and 9, *above, left*). This site is particularly advantageous because the nearby banked cartilage can be retrieved more conveniently when the new ear is lifted later from the head (Fig. 9, *above, second from left*). Furthermore, this scalp site seemingly provides better nourishment for the banked cartilage than does the subcutaneous chest region.

When harvesting this cartilage wedge material during the first-stage procedure, I split the cartilage in situ, which makes available a wider portion of cartilage, to achieve maximum projection of the ear (Fig. 10, *above*, and *second row*). This technique consists of shaving the outer cartilage from the rib, and it deliberately violates Gibson's[37] balanced cross-sectional principles, causing the cartilage wedge to warp into an ideal shape for the posterior conchal wall that it will form (Fig. 10, *below, left*). This method of tissue harvest leaves the inner cartilage lamella intact, once again maximizing chest wall integrity and minimizing deformity (Fig. 10, *above*, and *second row, right*).

Tragus Construction

Construction of a tragus can do much to improve the appearance of the constructed ear. Although I often create the tragus with tissue grafts from the opposite ear, making it possible to adjust projection of the normal auricle for better frontal symmetry,[21] I also use an alternative method of creating the tragus as an integral strut of the original framework during its initial fabrication. I achieve this with a small piece of rib cartilage that is first fastened to the frame, creating the antitragal eminence (Fig. 3, *above, left*, and *below, left*). The strut is thinned on one side and then curved around and affixed by its distal tip with a clear nylon suture that stretches across to crus helix of the frame. The result is a delicate tragus which flows naturally from the main framework through an arched intertragic notch (Fig. 3, *above, right*, and *below, right*). This method of tragus con-

struction is particularly advantageous in bilateral microtia where there is no source for special grafts of composite tissue.

Utilizing Vestiges

When dealing with the classic grade III, sausage-shaped microtic remnant, the surgical plan is always quite clear (Fig. 8, *above*). Using remnants is far more challenging when more ear exists (Fig. 7). In grade II conchal form microtia, one must decide whether to expand the existing remnant (Fig. 7, *above*), build upon it (Fig. 7, *below*), or leave it alone and merely reduce the size of the opposite, normal ear.

Long-Term Results of Microtia Repair

As with the first 500 microtia patients, a questionnaire survey was sent to the last 500 to evaluate the benefits of auricular repair on 1000 surgically repaired microtia patients. Although many of the author's patients came from a distance and were difficult to follow, a 50.8 percent response was obtained. This number of responses (508) has provided enough data to present valid information regarding a long-term outcome of ear repair. Follow-up ranged from 1 to 18 years, with an average of 7.7 years. The following was provided through survey data.

Durability of Constructed Auricle

Ears constructed from autogenous tissues withstand trauma remarkably well. Despite more than 70 cases of major trauma to surgically constructed ears, all healed without incidence. These traumatic episodes included severe blows during contact sports, abrasive injuries from wrestling and football scuffles, insect bites and bee stings, a human bite, and a dog bite.

These ears also retain their form over the years. The survey showed no instances of softening or shrinkage of the cartilaginous frameworks. As reported previously, ears constructed from autogenous cartilage in younger patients probably can be expected to grow.[5]

Psychological and Emotional Benefit

As one would expect, the survey again demonstrated that the impact of an unrepaired microtic deformity becomes greater to patient and family as the child enters school and approaches adolescence. Additionally, the survey demonstrated that the greater the emotional impact of the deformity, the greater the relief provided by its repair. A detailed analysis of the long-term emotional benefits of microtia repair is reported elsewhere.[38]

Burt Brent, M.D.
2995 Woodside Rd., Suite 300
Woodside, Calif. 94062
ears2you@best.com

REFERENCES

1. Tanzer, R. C. Discussion of Silastic Framework Complications. In R. C. Tanzer and M. T. Edgerton (Eds.), *Symposium on Reconstruction of the Auricle.* St. Louis: Mosby, 1974. Pp. 87–88.
2. Steffensen, W. H. Comments on reconstruction of the external ear. *Plast. Reconstr. Surg.* 16: 194, 1955.
3. Tanzer, R. C. Microtia: A long-term follow-up of 44 reconstructed auricles. *Plast. Reconstr. Surg.* 61: 161, 1978.
4. Brent, B. The correction of microtia with autogenous cartilage grafts: I. The classic deformity? *Plast. Reconstr. Surg.* 66: 1, 1980.
5. Brent, B. Auricular repair with autogenous rib cartilage grafts: Two decades of experience with 600 cases. *Plast. Reconstr. Surg.* 90: 355, 1992.
6. Wellisz, T. Reconstruction of the burned external ear with a Medpor porous polyethylene pivoting helix framework. *Plast. Reconstr. Surg.* 91: 811, 1993.
7. Bresnick, S. D., and Reinsch, R. F. Reconstructive Techniques for Salvage of the Medpore Ear Reconstruction. Presented at Ear Reconstruction '98: Choices for the Future, Chateau Lake Louise, Canada, March 5, 1998.
8. Williams, J. D., Romo, T., III, Sclafani, A. P., and Cho, H. Porous high-density polyethylene implants in auricular reconstruction. *Arch. Otolaryngol. Head Neck Surg.* 123: 578, 1997.
9. Young, F. Cast and precast cartilage grafts: Their use in the restoration of facial contour. *Surgery* 15: 735, 1944.
10. Peer, L. A. Reconstruction of the auricle with diced cartilage grafts in a Vitallium ear mold. *Plast. Reconstr. Surg.* 3: 653, 1948.
11. Cao, Y., Vacanti, J. P., Paige, K. T., Upton, J., and Vacanti, C. A. Transplantation of chondrocytes utilizing a polymer-cell construct to produce tissue-engineered cartilage in the shape of a human ear. *Plast. Reconstr. Surg.* 100: 297, 1997.
12. Ting, V., Sims, C. D., Brecht, L. E., and McCarthy, J. G. In vitro prefabrication of human cartilage shapes using fibrin glue and human chondrocytes. *Ann. Plast. Surg.* 40: 413, 1998.
13. Saadeh, P. B., Brent, B., Longacre, M., et. al. Human cartilage engineering: Chondrocyte extraction, proliferation, and characterization for construct development. *Ann. Plast. Surg.* 42: 509, 1999.
14. Song, Y., and Song, Y. An improved one-stage total ear reconstruction procedure. *Plast. Reconstr. Surg.* 71: 615, 1983.
15. Brent, B. An improved one-stage total ear reconstruction procedure (Discussion). *Plast. Reconstr. Surg.* 71: 623, 1983.
16. Thomson, H. G., Kim, T. Y., and Ein, S. H. Residual problems in chest donor sites after microtia recon-

struction: A long-term study. *Plast. Reconstr. Surg.* 95: 961, 1995.
17. Ohara, K., Nakamura, K., and Ohta, E. Chest wall deformities and thoracic scoliosis after costal cartilage graft harvesting. *Plast. Reconstr. Surg.* 99: 1030, 1997.
18. Brent, B. Ear reconstruction with an expansile framework of autogenous rib cartilage. *Plast. Reconstr. Surg.* 53: 619, 1974.
19. Tanzer, R. C. Total reconstruction of the auricle: The evolution of a plan of treatment. *Plast. Reconstr. Surg.* 47: 523, 1971.
20. Brent, B. Modification of the stages in total reconstruction of the auricle (Discussion). *Plast. Reconstr. Surg.* 93: 267, 1994.
21. Brent, B. Total Auricular Construction with Sculpted Costal Cartilage. In B. Brent (Ed.), *The Artistry of Reconstructive Surgery.* St. Louis: Mosby, 1987. Pp. 113–127.
22. Richards, R. N., McKenzie, M. A., and Meharg, G. E. Electroepilation (electrolysis) in hirsutism: 35,000 hours' experience on the face and neck. *J. Am. Acad. Dermatol.* 15: 693, 1986.
23. Wheeland, R. G. Laser-assisted hair removal. *Dermatol. Clin.* 15: 469, 1997.
24. Dalrymple, J. C., and Monaghan, J. N. Treatment of hidradenitis suppurativa with the carbon dioxide laser. *Br. J. Surg.* 74: 420, 1987.
25. Sasaki, G. Personal communication, 1998.
26. Lask, G., Elman, M., and Slatkine, M. Laser-assisted hair removal by selective photothermolysis: Preliminary results. *Dermatol. Surg.* 23: 737, 1997.
27. Nanni, C. A., and Alster, T. S. Optimizing treatment parameters for hair removal using a topical carbon-based solution and 1064-nm Q-switched neodymium: YAG laser energy. *Arch. Dermatol.* 133: 1546, 1997.
28. Littler, C. M. Laser hair removal in a patient with hypertrichosis lanuginosa congenita. *Dermatol. Surg.* 23: 705, 1997.
29. Dierickx, C. C., Grossman, M. C., Farinelli, W. A., and Anderson, R. R. Permanent hair removal by normal-mode ruby laser. *Arch. Dermatol.* 134: 837, 1998.
30. Nagata, S. Modification of the stages in total reconstruction of the auricle: Part I. Grafting the three-dimensional costal cartilage framework for lobule-type microtia. *Plast. Reconstr. Surg.* 93: 221, 1994.
31. Firmin, F. Ear reconstruction in cases of typical microtia: Personal experience based on 352 microtic ear corrections. *Scand. J. Plast. Reconstr. Hand Surg.* 32: 35, 1998.
32. Brent, B., and Byrd, H. S. Secondary ear reconstruction with cartilage grafts covered by axial, random, and free flaps of temporoparietal fascia. *Plast. Reconstr. Surg.* 72: 141, 1983.
33. Firmin, F. Controversies in Autogenous Auricular Reconstruction. Presented at Ear Reconstruction '98: Choices for the Future, Chateau Lake Louise, Canada, March 4, 1998.
34. Weerda, H. Discussion of personal technique in Panel by Brent, B. "Solving problems in autogenous auricular reconstruction." Presented at Ear Reconstruction '98: Choices for the Future, Chateau Lake Louise, Canada, March 5, 1998.
35. Brent, B. Development of Ear Reconstruction: The Past, Present and Future. Keynote address, presented at Ear Reconstruction '98: Choices for the Future, Chateau Lake Louise, Canada, March 4, 1998.
36. Nagata, S. Two-stage Total Auricular Reconstruction with Autogenous Costal Cartilage. Presented at Ear Reconstruction '98: Choices for the Future, Chateau Lake Louise, Canada, March 4, 1998.
37. Gibson, T., and Davis, W. B. The distortion of autogenous cartilage grafts: Its cause and prevention. *Br. J. Plast. Surg.* 10: 257, 1957.
38. Brent, B. The pediatrician's role in caring for patients with congenital microtia and atresia. *Pediatr. Ann.* 28: 374, 1999.